

External Anogenital Warts

What's New:

Speculum vaginal examination only required if internal warts are suspected (due to vulvovaginal symptoms or warts which may extend into introitus)

Currently global shortages of podophyllotoxin containing treatments

Introduction

Warts are the most common viral STI and patients can often be managed in a Primary Care setting without the need for onward referral to specialist services.

This guideline details how care should be provided to patients 16 years of age and older.

Patients under 12 should be referred to a paediatrician with child protection experience.

For patients aged 12 to 15 inclusive please refer to the West of Scotland Sexual Health Managed Clinical Network Guideline 'Young People: common STIs and other Genital Infections in 12 to 15 year olds'.

Clinical Aspects

Presentation

- Symptoms include noticing the presence of new lumps/growths in the anogenital area.
- Other symptoms include local irritation, bleeding or discomfort.
- More commonly warts present as soft cauliflower-like growths of varying size.
- Less commonly, the warts are flat, plaque-like or pigmented.
- On rare occasions large warts present with secondary infection and maceration.
- Rarely, warts may grow more rapidly and infiltrate local tissue or cause local erosion.
- Perianal lesions are common in both sexes and may not necessarily be associated with the practice of anal sex, due to the regional nature of infection with HPV. They are however seen more commonly in men who have sex with men (MSM). Warts inside the anal canal are usually associated with penetrative anal sex.
- Warts can appear or increase in size during pregnancy.

Diagnosis and assessment

- Warts are usually diagnosed by visible inspection under good illumination.
- Examination of the genitalia and perianal skin is essential to recognise the full extent of the warts.
- All patients should be offered a full sexual health screen to include HIV testing particularly if patient has extensive or non resolving warts
- Application of 5% acetic acid to reveal subclinical or latent infection is not recommended.
- The differential diagnosis of warts includes physiological features, dermatoses and other infections such as molluscum contagiosum. If uncertain, seek the opinion of a senior doctor.
- Occasionally magnification (eg with a colposcope) and / or biopsy (in atypical lesions) may be needed.
- Biopsy may be advisable for lesions that do not respond to treatment.
- Speculum vaginal examination only required if internal warts are suspected (due to vulvovaginal symptoms or warts which may extend into introitus)
- Intravaginal and cervical warts do not require treatment unless symptomatic. Patients with cervical lesions where there is diagnostic uncertainty or clinical concern should be referred for colposcopy.

WOS External Anogenital Warts Guideline	APPROVED: MAY 2024
WOS MCN CLINICAL GUIDELINES GROUP	VERSION: FINAL 8.1 Last Updated: MAY 2024
REVIEW DATE: May 2028 PAGE NUMBER: 1 of 6	COPIES AVAILABLE: www.wossexualhealthmcn.scot.nhs.uk

- Ensure cervical smears are up to date. Most anogenital warts are benign and caused by HPV 6 and 11, which are of low oncogenicity. The NHS cervical Screening Programme recommends that no changes are required to screening intervals in women with anogenital warts.
- Proctoscopy is not routinely performed in patients with external genital warts unless there are anorectal symptoms (such as irritation, bleeding or discharge), warts at the anal margin where the upper limit cannot be visualised or other diagnostic tests are required. Intra-anal warts should only be treated if symptomatic. If uncertain, discuss with a senior doctor.
- Meatoscopy/urethroscopy should be performed by urologists if there is difficulty in visualising the full extent of intra-meatal warts.
- Some patients present with intraepithelial neoplastic lesions in the anogenital region, either with or without coincidental benign warts. This includes intraepithelial neoplasia affecting the vulva (VIN), vagina (VaIN), perianal area (PAIN), anus (AIN) and penis (PIN). The diagnosis of intraepithelial neoplasia is made through histology. The presence of pigmentation, depigmentation, pruritus, underlying immune-deficiency, and prior history of intraepithelial neoplasia on the same or distant anogenital sites may raise suspicion of anogenital neoplasia.

Wart Assessment

The following factors should be documented.

- Site(s) and distribution of warts (vulva, meatus, glans etc.).
- Approximate number (single /multiple) & area of warts (especially if more than 4cm²).
- Morphology: keratinised or non-keratinised (those on moist, soft non-hair bearing tissue tend not to have a layer of keratin).
- Any other notable features (e.g. pigmentation).
- Patient factors influencing therapy (e.g. pregnancy, immunosuppression, ability to re-attend).

Management

In General

- No treatment may be an option, as about 30% of patients will experience spontaneous clearance of warts over a period of up to 6 months. However most patients seek treatment for the discomfort, anxiety, distress or the social unacceptability that warts cause.
- The objective of treatment is removal of visible warts. Eradication of HPV is not an achievable goal with current therapies and treatment has no measurable effect on transmission rates between partners.
- The evidence base to direct first and second line treatments is not strong.
- All treatments have significant failure and relapse rates (see Appendix).
- Treatment may involve discomfort and local skin reactions.
- Treatment choice depends on the patient preference as well as morphology, number, and distribution of warts.
- Treatment decisions should be made after discussing the appropriate options with the patient.
- Provision of written information on management of treatment side effects is recommended.
- Very large wart lesions should be considered for surgical treatment.
- Topical anaesthetics (eg lidocaine cream, EMLA®) can be used prior to cryotherapy particularly when treating larger lesions.
- Caution should be exercised using any modality of treatment because of the danger of oedema and necrosis of surrounding tissue.

WOS External Anogenital Warts Guideline	APPROVED: MAY 2024
WOS MCN CLINICAL GUIDELINES GROUP	VERSION: FINAL 8.1 Last Updated: MAY 2024
REVIEW DATE: May 2028 PAGE NUMBER: 2 of 6	COPIES AVAILABLE: www.wossexualhealthmcn.scot.nhs.uk

Management Algorithm for the Initial Management of External Genital and Peri-anal Warts in Non Pregnant People

Special situations

Urethral meatus

- If the base of the lesions is seen, treatment with cryotherapy
- Lesions deeper in the urethra should be surgically ablated under direct vision, which may require referral to a urologist or the use of a meatoscope.

Management of warts in pregnancy

- Refer to WOS Guideline Pregnancy and STIs

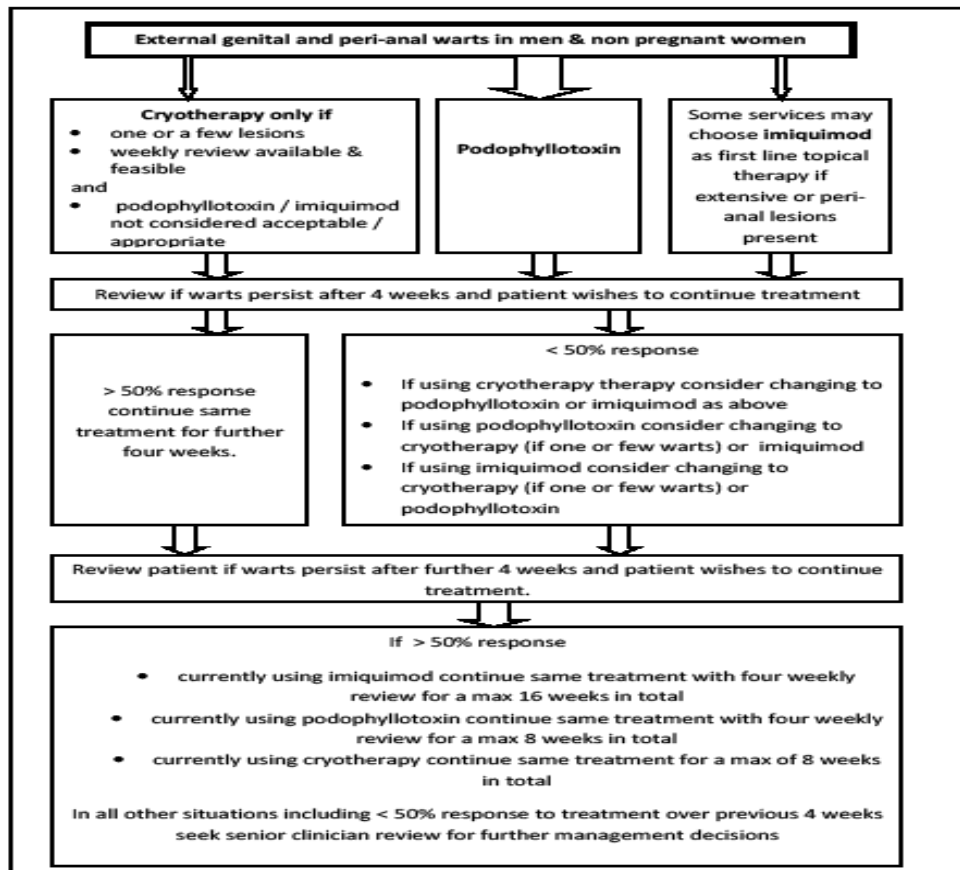
Lesions in the immunosuppressed or extensive carpet warts

- These may be refractory to treatment and should be discussed with a senior doctor from the outset.

Initial Management of External Genital and Peri-anal Warts in Non Pregnant People

(excluding intrameatal, extensive carpet warts and warts in the immunosuppressed – refer to ‘Special considerations’ above)

Also refer Treatment Notes’ for general and specific information for each treatment modality



WOS External Anogenital Warts Guideline	APPROVED: MAY 2024
WOS MCN CLINICAL GUIDELINES GROUP	VERSION: FINAL 8.1 Last Updated: MAY 2024
REVIEW DATE: May 2028 PAGE NUMBER: 3 of 6	COPIES AVAILABLE: www.wossexualhealthmcn.scot.nhs.uk

Treatment Notes

Important Considerations:

- **Latex condoms** may be weakened by podophyllotoxin and imiquimod.
- Clinicians should avoid the inadvertent exposure of pregnant women to podophyllotoxin and imiquimod which potentially may arise though the use of these products in a sexual partner. The area which is under treatment in a partner should be thoroughly washed before sexual contact occurs.
- GUM Consultants who are referred recalcitrant warts for review may consider additional therapeutic options such as **trichloroacetic acid**.
- **Surgical excision or hyfrecation** should be considered for warts which have failed to respond.
- **Biopsy** may be necessary in some cases, eg, unusual appearance or failing to respond to treatment.

Treatment Choice:

In choosing between self-applied agents, podophyllotoxin and imiquimod appear broadly equivalent in safety and efficacy. However its lower cost, shorter treatment duration and faster mode of action may make podophyllotoxin preferred as a first choice. Sinecatechins have similar clearance rates in trials but no randomised head-to-head comparisons with other treatments have been performed and the frequency of dosing(three times daily) may be a barrier to adherence

Podophyllotoxin (WARTICON® and CONDYLINE®) are purified extracts of podophyllin suitable for self administration

- Warticon® and Condyline® are licensed for the treatment of warts of the penis or the external female genitalia.
- Supervision by medical staff is recommended when the lesion area treated is greater than 4 cm².
- Warticon® and Condyline® are not licensed for use of extragenital warts, however Warticon® is commonly used on external lesions at all sites.
- Podophyllotoxin solution (0.5%) is preferred over the 0.15% cream formulation where it can be easily applied owing to slightly superior efficacy
- Condyline® is only available as a 0.5% alcoholic solution.
- Treatment cycles consist of twice daily application for 3 days followed by 4 days rest for 4 cycles.
- Warticon® and Condyline® should not be used in pregnancy and lactation.
- It should not be used on broken skin.
- Treatment should be discontinued if significant side effects (eg soreness, ulceration).
- Consider repeat cycles of treatment if the warts are responding although this is not licensed (see algorithm).
- Unprotected sexual contact should be avoided soon after application because of a possible irritant effect on the partner.

Imiquimod (ALDARA®) is an immune response modifier.

- It is licensed for external genital and peri-anal warts.
- It should not be used in pregnancy and breast feeding.
- It should be applied three times per week (example: Monday, Wednesday and Friday) and washed off 6 to 10 hours later.
- It frequently causes local skin / mucous membrane irritation when applied for anogenital warts. This may be due to narrow therapeutic margin. Temporary halting of treatment may be required to manage side effects.

WOS External Anogenital Warts Guideline	APPROVED: MAY 2024
WOS MCN CLINICAL GUIDELINES GROUP	VERSION: FINAL 8.1 Last Updated: MAY 2024
REVIEW DATE: May 2028 PAGE NUMBER: 4 of 6	COPIES AVAILABLE: www.wossexualhealthmcn.scot.nhs.uk

- Unprotected sexual contact should be avoided soon after application because of a possible irritant effect on the partner.
- Use should continue until the clearance of visible genital or perianal warts or for a maximum of 16 weeks per episode of warts with 4 weekly reviews.
- Response to treatment may be delayed for some weeks. Extending treatment to 20 weeks or beyond in those who are showing a response is common practice but there is no trial evidence concerning this.
- Clinical trials of imiquimod versus placebo have shown response rates comparable with other topical agents. A lower relapse rate has been suggested, but clinical trials comparing relapse after other topical therapies have not been conducted.
- Normally used for refractory warts which have failed to respond to other treatments, or warts which have been assessed by a senior doctor/senior nurse and are thought likely to be refractory to treatment (eg extensive carpet warts). Some services may choose to use first line for keratinised lesions when cryotherapy is not an option.
- Immune deficiency may not be a contraindication for the use of imiquimod topically for anogenital warts and it has been used in HIV positive subjects but use in patients who are immunosuppressed should be discussed with a senior clinician.
- Has the potential to exacerbate inflammatory skin conditions; it should be used with caution in patients with autoimmune conditions although systemic absorption from topical treatment is likely to be negligible.

Cryotherapy is the name given to treatments which involve liquid nitrogen spray freezing the skin, causing cytolysis (cell breakdown) resulting in necrosis

- Suitable for a small number of lesions
- Success partly depends on ability to treat at regular (normally weekly) intervals. Services report high rates of non attendance for appointments. These factors should be taken into account when deciding whether home treatment with topical agents may be preferable.
- Treatment of choice in pregnancy and intrameatal warts (see special considerations).
- Treatment should be applied until a halo of freezing has been established a few millimetres round the treated lesion. A freeze, thaw, freeze technique should be used.
- Response rates depend on size and chronicity of the lesions.
- Usually repeated at weekly intervals; lack of response after four weeks should prompt consideration of an alternative treatment modality.
- Liquid nitrogen is a hazardous substance which requires great care during handling. Only health professionals who have received appropriate training may administer cryotherapy.
- Caution: The storage and handling of liquid nitrogen should be undertaken according to health and safety guidance (see British Oxygen www.bocindustrial.co.uk), COSHH Essentials (www.coshessentials.org.uk) and the Health & Safety Executive (www.hse.gov.uk)

Information giving

- Before information is given, an assessment must be made of the patient’s existing preconceptions and concerns.
- Information should cover epidemiology, transmission, natural history, treatment and partner issues varying the order and pace of information delivery to suit the needs of the patient.
- All patients should be given written information (NHS inform or BASHH Patient Leaflet).
<https://www.nhsinform.scot/illnesses-and-conditions/sexual-and-reproductive/genital-warts/#:~:text=Treatment%20for%20genital%20warts%20is,have%20treatment%20for%20genital%20warts> https://www.bashh.org/resources/52/genital_warts
- For some patients the psychological impact of warts is the worst aspect of the disease. Where psychological distress is apparent, referral for counselling may be appropriate.
- Several treatment attempts are usually needed before warts subside.

WOS External Anogenital Warts Guideline	APPROVED: MAY 2024
WOS MCN CLINICAL GUIDELINES GROUP	VERSION: FINAL 8.1 Last Updated: MAY 2024
REVIEW DATE: May 2028 PAGE NUMBER: 5 of 6	COPIES AVAILABLE: www.wossexualhealthmcn.scot.nhs.uk

Epidemiology

- HPV infection is very common and most infections do not result in physical genital tract lesions, and resolve spontaneously within a year
- Gardasil® has been used in the HPV immunisation programme since Sept 2012. This is now a nine-valent HPV vaccine. Types 6 & 11 account for approximately 90% of genital warts of genital warts. The prevalence of HPV 6 and 11 in the UK has fallen in vaccinated groups with an associated 35% decline in the number of genital warts diagnosed between 2010–2019

Transmission

- The majority of individuals infected with HPV have no visible warts.
- The mode of transmission is most often by sexual contact but HPV may be transmitted prenatally and genital lesions resulting from infection from hand warts have been reported in children.
- There is no good evidence of fomite transmission
- Transmission studies have quoted male to female transmission at 3 months of 54% and female to male transmission of 71%.
- HPV transmission can occur from asymptomatic individuals.
- Consistent condom use has been shown to reduce the risk of acquisition of HPV infection and genital warts (in the order of about 30%). They may reduce the recurrence when both partners are infected, although the extent to which recurrence is due to reinfection is not known.

Natural History

- The infection is multicentric from the outset and the location of visible lesions does not accurately reflect the original site of inoculation. e.g. the presence of perianal warts does not imply anal intercourse has occurred.
- The incubation period between HPV acquisition and the appearance of visible warts is very variable but generally in the range 3 weeks to 8 months, but can be as long as 18 months, with some evidence that it is longer in men.
- Some apparently new infections will actually be recurrent disease.
- Warts can appear at any time if immunity is impaired e.g. in pregnancy, HIV co-infection and smokers.
- Treatment of sexual partners makes no significant impact on the natural history of genital warts.
- Smokers may respond less well to treatment than non smokers.
- About 30% of patients will experience spontaneous clearance of warts over a period of up to 6 months.

Partner Attendance

Partners should be encouraged to attend if visible warts present.

HPV Vaccination

Trials have so far failed to demonstrate a significant therapeutic benefit of vaccine for those with existing warts either for clearance of warts or a reduction in subsequent recurrence. The use of HPV vaccine in the treatment of warts is not recommended. It is recommended that eligible individuals either with or without pre-existing AGW should be offered vaccination, in accordance with national guidance

References

United Kingdom National Guideline on the Management of Anogenital Warts in Adults, 2024
Clinical Effectiveness Group (British Association for Sexual Health and HIV [Accessed April 2024])
<http://www.bashh.org/documents/UK%20national%20guideline%20on%20Warts%202015%20FINAL.pdf>

WOS External Anogenital Warts Guideline	APPROVED: MAY 2024
WOS MCN CLINICAL GUIDELINES GROUP	VERSION: FINAL 8.1 Last Updated: MAY 2024
REVIEW DATE: May 2028 PAGE NUMBER: 6 of 6	COPIES AVAILABLE: www.wossexualhealthmcn.scot.nhs.uk